Oral mucosal lesions

- **Ulcerative conditions:**
  - Immune mediated disorders

Recurrent aphthous stomatitis

Minor aphthous ulcers :

- ✓ the most commonly encountered form.
- ✓ single , painful ,oval ulcer that is less than 0.5 cm in diameter , covered by a yellow fibrinous membrane and surrounded by an erythematous halo.

• **Fig. 9-5 Minor Aphthous Ulcerations.** Two ulcerations of differen sizes located on the maxillary labial mucosa.

Major Aphthous Ulcers

- The most severe expression of aphthous stomatitis .
- Lesions are larger (>0.5 cm) and more painful and persist longer than minor aphthae .
- appear crateriform clinically and heal with scar formation .

• **Fig. 9-8 Major Aphthous Ulceration.** Large, irregular ulceration of the soft palate.

• **Fig. 9-10 Major Aphthous Ulceration. A,** Large ulceration of the left anterior buccal mucosa. **B,** Same lesion after 5 days of therapy with betamethasone syrup used in a swish-and-swallow method. The patient was free of pain by the second day of therapy. The ulceration healed completely during the next week.

Herpetiform aphthous ulcers

- recurrent crops of small ulcers .
- movable mucosa is predominantly affected , palatal and gingival mucosa may also involves .

• **Fig. 9-9 Herpetiform Aphthous Ulcerations.** Numerous pinhead ulcerations of the ventral surface of the tongue, several of which have coalesced into larger, more irregular areas of ulceration.

Behçet's syndrome

- rare multisystem inflammatory disease in which recurrent oral aphthae are a consistent feature .
- pustular erythema nodosum –like skin lesions

• **Fig. 9-11 Behçet Syndrome.** Diffuse erythema surrounding numerous irregular ulcerations of the soft palate.

Mucosal and Skin Conditions:

- **Lichen planus**

• **Fig. 16-91 Lichen Planus.** The cutaneous lesions on the wrist appear as purple, polygonal papules.

• **Fig. 16-92 Lichen Planus.** Closer view of a skin lesion of lichen planus. Careful examination shows a network of fine white lines (Wickham striae) on the surface of the papules.

Reticular lichen planus

• **Fig. 16-93 Lichen Planus.** The interlacing white lines and papules are typical of reticular lichen planus involving the buccal mucosa, the most common site of oral involvement.

• **Fig. 16-95 Lichen Planus.** Reticular lesions of the lower lip vermilion.

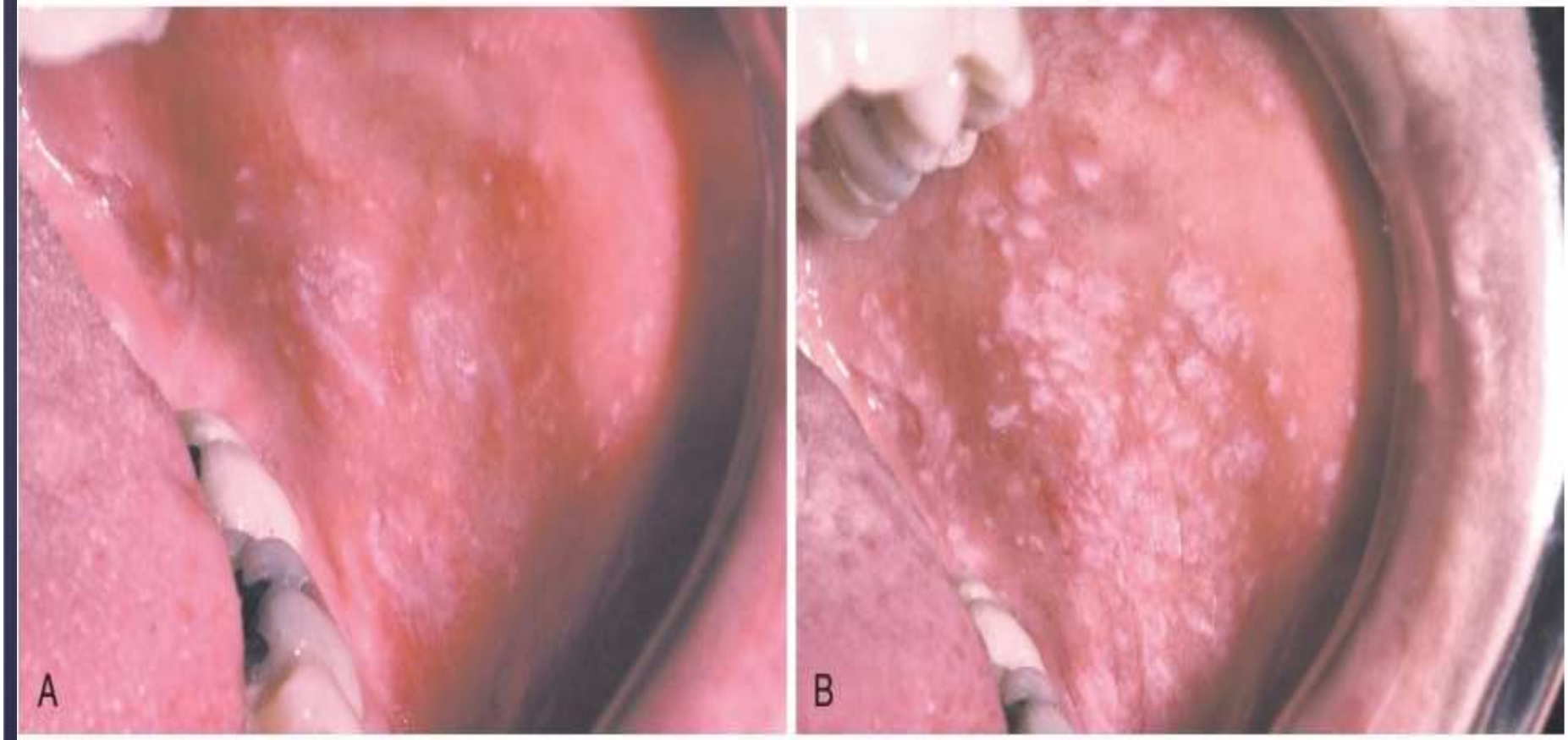

• **Fig. 16-96 Lichen Planus. A,** A middle-aged woman with mild reticular lichen planus of the left buccal mucosa. **B,** Same patient 2 weeks later, showing exacerbation of the lesions. Such waxing and waning is characteristic of lichen planus.

• **Fig. 16-97 Lichen Planus.** With involvement of the dorsal tongue by reticular lichen planus, the characteristic interlacing striae seen in the buccal mucosal lesions are usually not present. Instead, smooth white plaques are typically observed replacing the normal papillary surface of the tongue.

Erosive lichen planus,

• **Fig. 16-98 Lichen Planus.** Ulceration of the buccal mucosa shows peripheral radiating keratotic striae, characteristic of oral erosive lichen planus.

• **Fig. 16-100 Lichen Planus.** Erosive lichen planus often appears as a desquamative gingivitis, producing gingival erythema and tenderness.

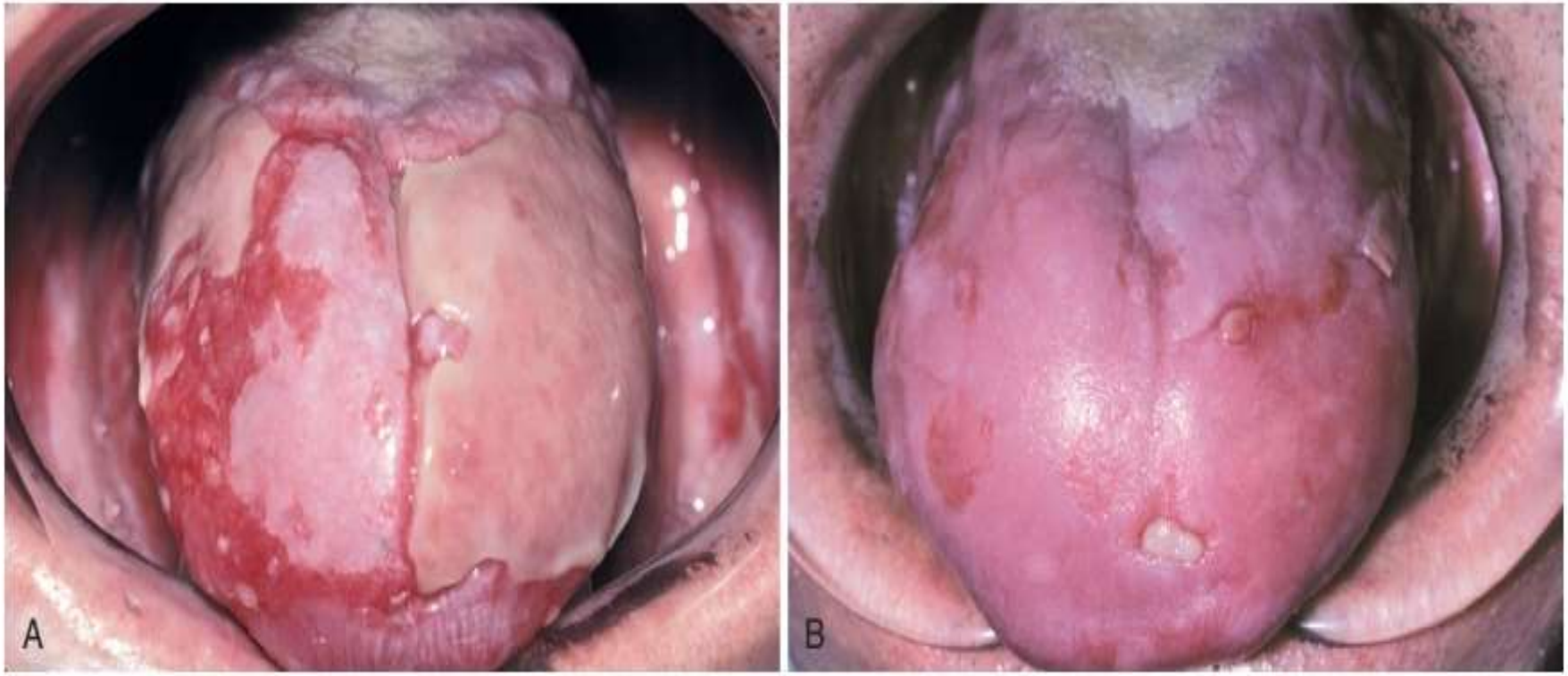

• **Fig. 16-99 Lichen Planus. A,** The dorsal surface of the tongue shows extensive ulceration caused by erosive lichen planus. Note the fine white streaks at the periphery of the ulcerations. **B,** Same patient after systemic corticosteroid therapy. Much of the mucosa has reepithelialized, with only focal ulcerations remaining.

Histopathologic Features :

- The reteridges may be absent or hyperplastic, but they classically have a pointed or "saw toothed" shape.

.

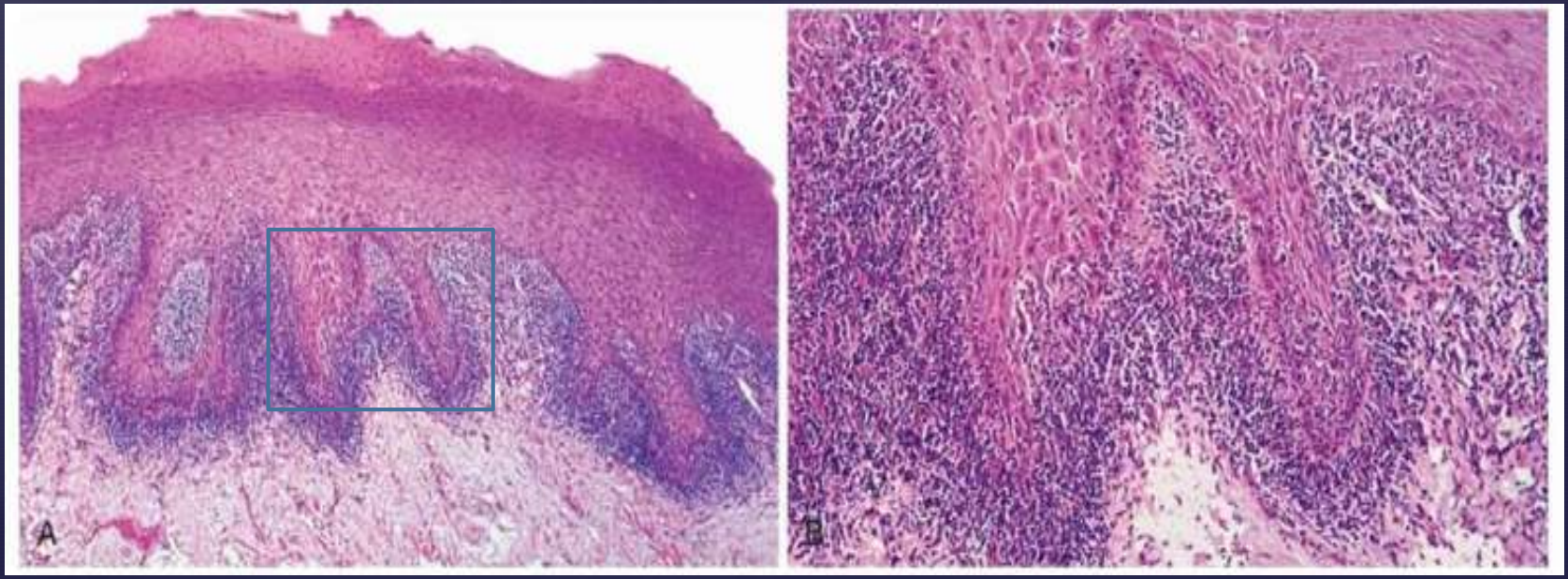

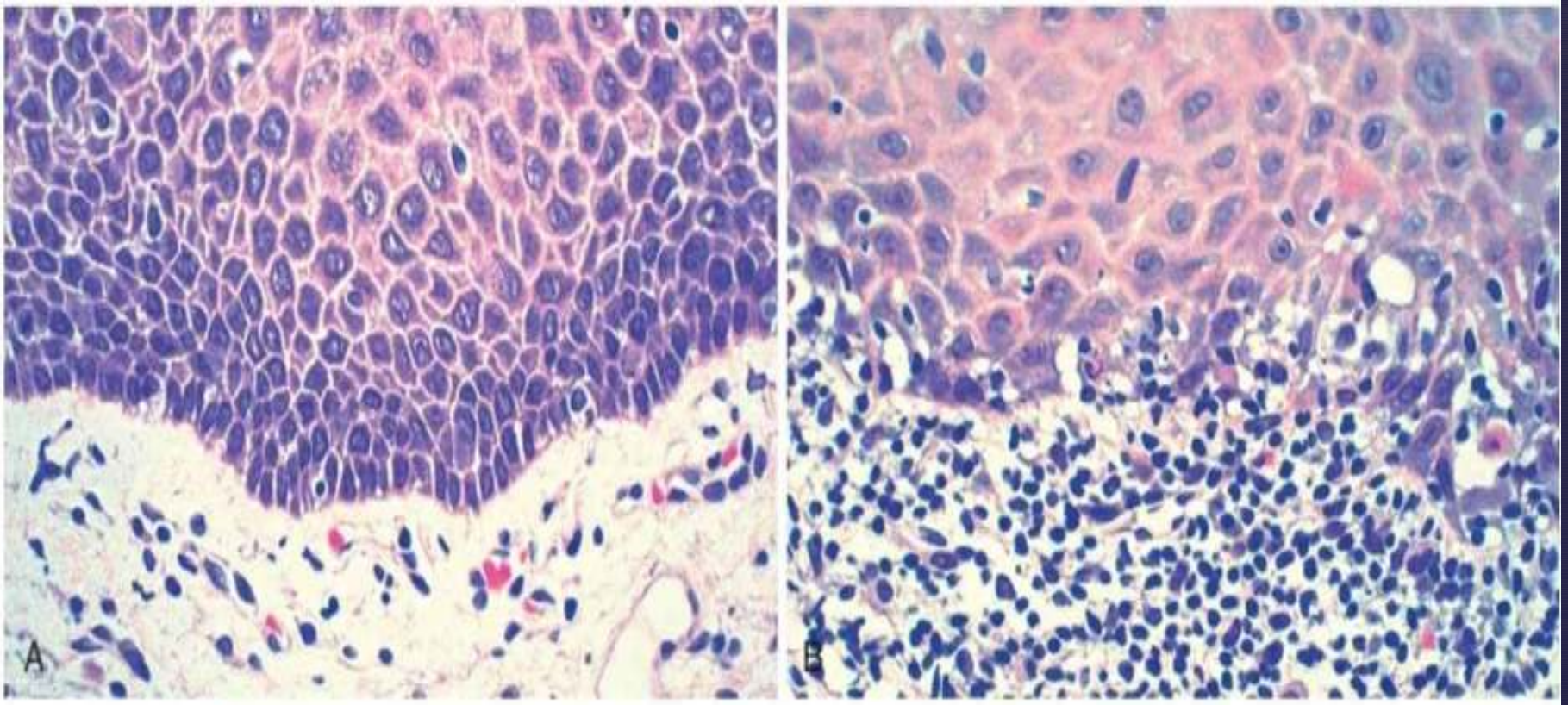

• **Fig. 16-102 Lichen Planus. A,** High-power photomicrograph of normal epithelium showing an intact basal cell layer and no inflammation. **B,** High-power photomicrograph of lichen planus showing degeneration of the basal epithelial layer and an intense lymphocytic infiltrate in the superficial lamina propria.

Erythema multiforme

(EM) is an acute self-limiting hypersensitivity reaction characterized by target skin lesions and /or ulcerative oral lesions .It has been divided in to two subtypes :a minor form , usually associated with an HSV target , and a major severe form triggered by certain systemic drugs

- The classic skin lesion of EM is the target or iris lesion .

• **Fig. 16-75 Erythema Multiforme.** The concentric erythematous pattern of the cutaneous lesions on the fingers resembles a target or bull's-eye.

- ✓ Orally ,ulcerative disease varying from a few aphthous –type lesions to multiple superficial widespread ulcers in EM major .

• **Fig. 16-76 Erythema Multiforme.** Focal hemorrhagic crusting of the lips is seen in conjunction with diffuse shallow ulcerations and erosions involving this patient's mandibular labial mucosa.

• **Fig. 16-77 Erythema Multiforme.** Same patient as Figure 16-76. Diffuse shallow ulcerations of varying sizes are noted on the right buccal mucosa. The patient had finished a course of sulfamethoxazole and trimethoprim for a urinary tract infection a few days before the onset of the lesions.

Stevens-Johnson syndrome

Chronic ulcerative stomatitis usually affects adult women. It may appear as desquamative gingivitis or as ulcerations of the tongue or buccal mucosa.

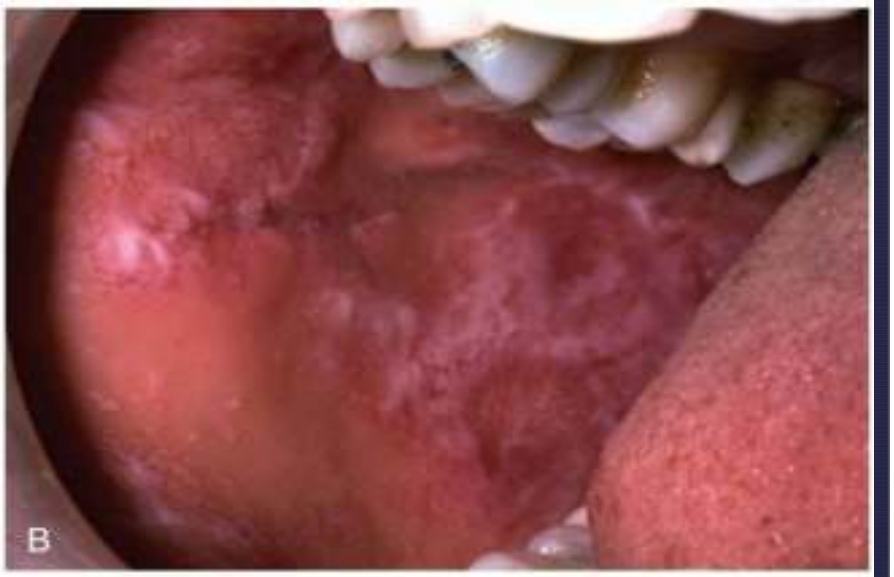

• **Fig. 16-105 Chronic Ulcerative Stomatitis. A,** Gingival lesions having a "desquamative gingivitis" presentation, requiring biopsy with direct immunofluorescence studies for diagnosis. **B,** Buccal mucosal involvement. The lesions appear somewhat lichenoid, although classic Wickham striae are not evident.

Histologically

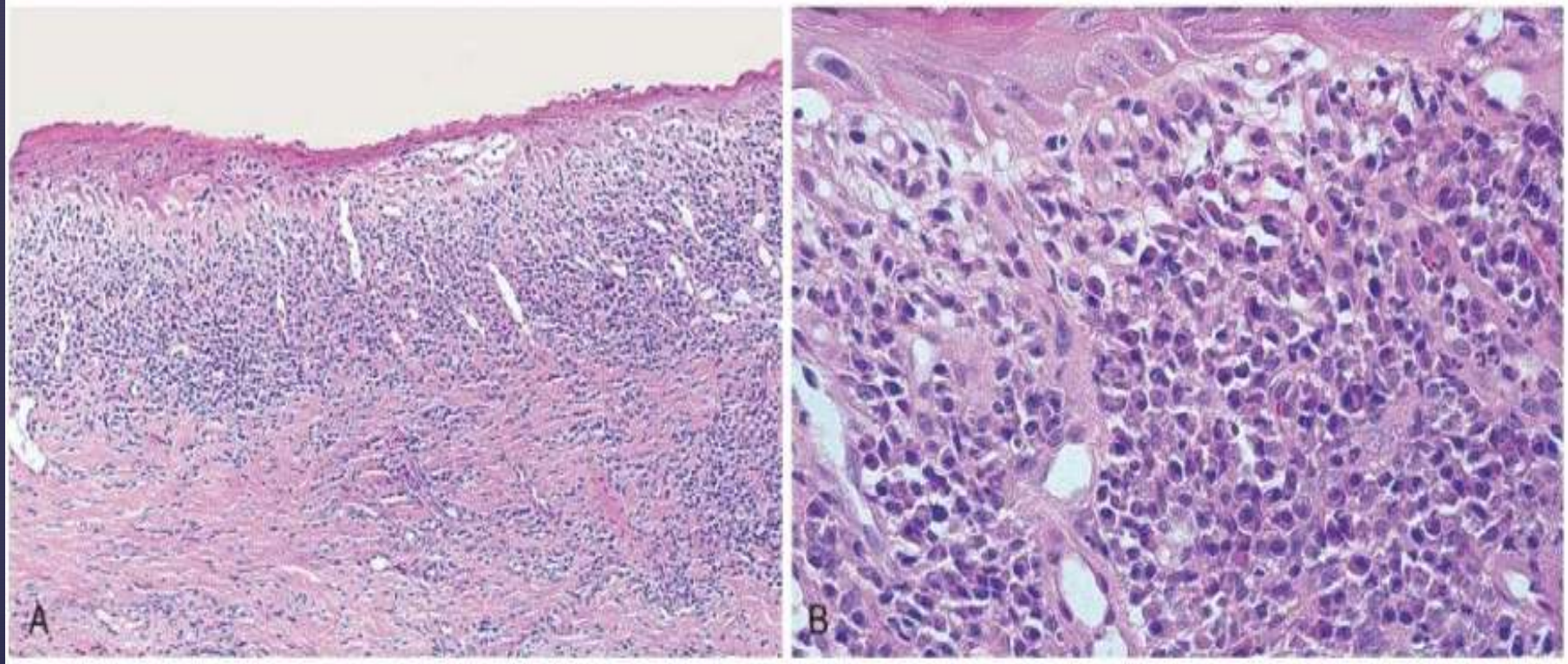

• **Fig. 16-106 Chronic Ulcerative Stomatitis. A,** Low-power photomicrograph showing epithelial atrophy with a heavy chronic inflammatory cell infiltrate in the superficial lamina propria. **B,** High-power photomicrograph showing interface degeneration of the basilar epithelium in association with the inflammation. Unlike lichen planus, this infiltrate includes numerous plasma cells, as well as lymphocytes.

Diagnosis

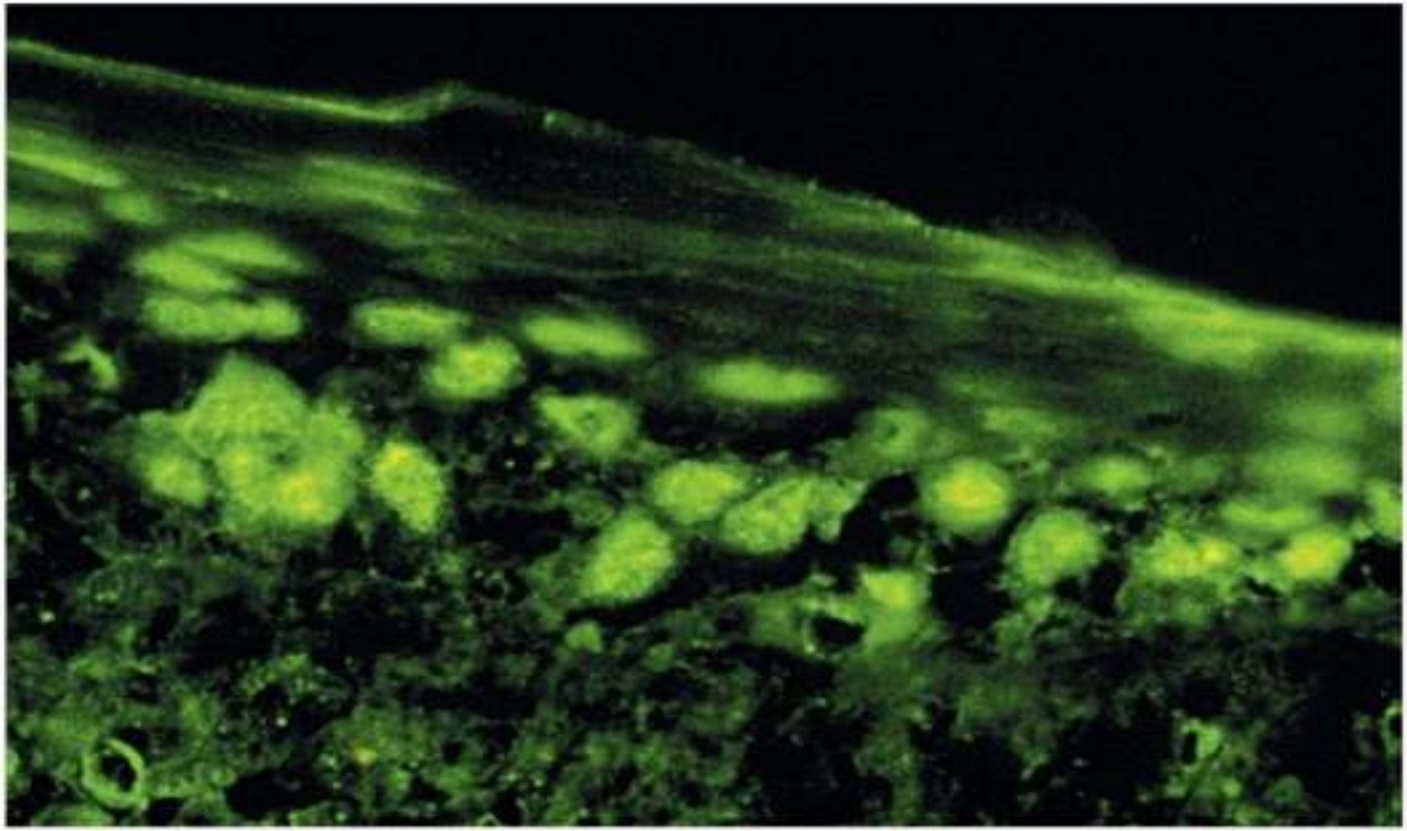

• **Fig. 16-107 Chronic Ulcerative Stomatitis.** Direct immunofluorescence studies show presence of IgG in the basal and parabasal epithelial nuclei.

Thank you